

## FerriScan® R2-MRI Fact Sheet – Thalassaemia and Iron Overload

Iron overload occurs when total body iron is increased through chronic blood transfusions or increased absorption of iron through the gastro-intestinal tract. Blood transfusion therapy is the major cause of iron overload in thalassaemia major and increased intestinal iron absorption is more significant in thalassaemia intermedia.

Excess iron deposits primarily in the liver, but once a threshold level is reached, iron loading may occur in other tissues such as the heart. Monitoring liver iron concentration therefore provides an early warning of possible future cardiac complications.

### Monitoring Iron Overload

Liver Iron Concentration (LIC) provides the best measure of total body iron stores, informing clinician decisions on initiation and adjustment of chelation therapy.

*Effective control of total body iron stores has been shown to significantly reduce the risk of cardiac disease and death in patients with thalassaemia major.<sup>1</sup>*

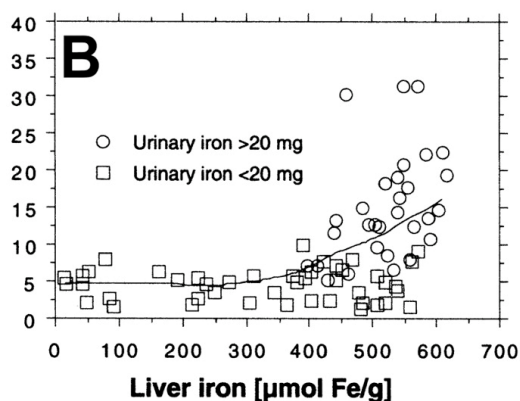
Serum ferritin measurements are an unreliable predictor of iron loading in thalassaemia major as they can be impacted by inflammation, fibrosis and other conditions.<sup>2</sup> Serum ferritin has been found to significantly underestimate iron loading in thalassaemia intermedia.<sup>3</sup> More particularly, in HbE thalassaemia, serum ferritin measurements have been shown to be of little clinical value in assessing body iron burden.<sup>4</sup>

### Why Measure Liver Iron?

It has been established that there is a relationship between liver and heart iron, but this relationship is longitudinal rather than cross-sectional.<sup>5</sup> High hepatic iron concentration is associated with cardiac iron overload in thalassaemia major.<sup>6</sup>

Changes in heart iron usually lag behind changes in liver iron. Therefore measurements of cardiac iron alone do not provide clinicians with a complete picture of a patient's body iron loading. In thalassaemia intermedia patients who have had minimal or no transfusions there may be no evidence of cardiac iron loading, yet significant liver iron overload.<sup>7</sup>

*Cardiac iron deposition generally occurs after LIC has reached a certain threshold in thalassaemia major*



14 subjects with transfusional iron overload and uncomplicated chelation history **Jensen et al (2003) Blood 101, 4632-9**

### Key FerriScan Features:

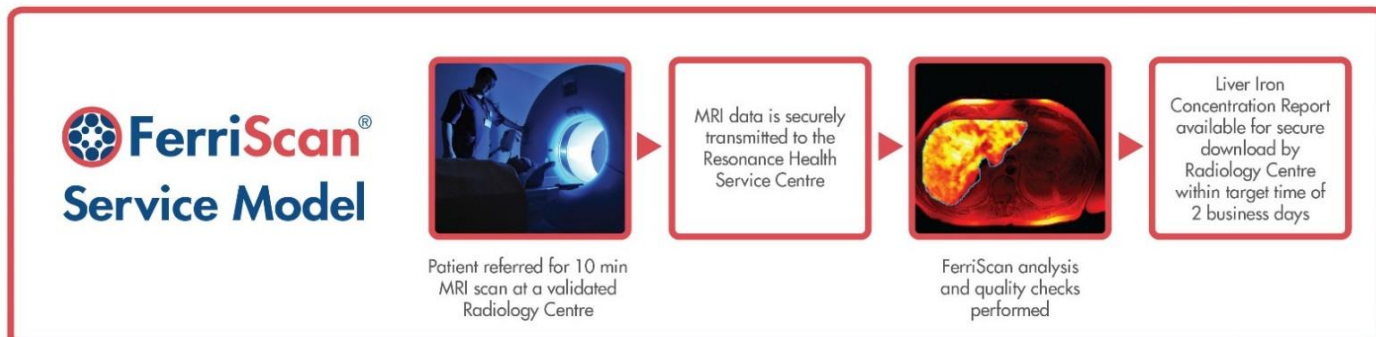
- ✓ FerriScan provides an accurate, validated MRI-based measurement of liver iron concentration
- ✓ FerriScan is non-invasive, requires no contrast agents and has a scan time of approximately 10 minutes
- ✓ FerriScan has high sensitivity and specificity for measuring LIC
- ✓ Image analysis and LIC reporting is performed at a central ISO 13485 certified Service Centre
- ✓ FerriScan has international regulatory clearance (USA, Europe, Australia)
- ✓ Results are available within a target time of two business days
- ✓ FerriScan can measure LIC over the entire range encountered in clinical practice<sup>3</sup>
- ✓ FerriScan results are clinically validated to be unaffected by inflammation, fibrosis or cirrhosis
- ✓ FerriScan requires no breath-hold and may therefore be used for paediatric patients
- ✓ Results are accurate, reliable and reproducible over time and between MRI centres and models of scanner
- ✓ There is no requirement for customers to purchase new software or hardware
- ✓ FerriScan is suitable for 1.5 Tesla MRI scanners
- ✓ FerriScan is charged per scan only

## FerriScan R2-MRI

The FerriScan patented analysis is applied to R2-MRI acquired images of the liver, creating a map of LIC and providing a mean LIC value calculated from a cross-sectional slice of liver tissue.

The LIC report returned to the MRI centre includes a table indicating the clinical relevance of the LIC result obtained.

*FerriScan is delivered to MRI centres as a service, with no hardware or software installation and no specialist training required.*



## FerriScan Validation

**Multi-centre validation of FerriScan** has been performed on five different scanners with a cohort of 233 thalassaemia patients, bringing to 338 the total number of patient FerriScans validated by biopsy.

- The calibration curve for the R2-MRI technique remains robust with no statistically significant deviations observed in the current study.
- No statistically significant differences in accuracy or precision of LIC measurements between the five scanners were observed.
- No detectable change in the calibration curve is caused by the use of deferasirox, the presence of fibrosis or use in very young children.<sup>8</sup>

The 2008 “Guidelines for the clinical management of Thalassaemia” (updated 2<sup>nd</sup> edition), Thalassaemia International Federation (TIF) states:

*“LIC can also now be measured using MRI techniques previously limited to a relatively narrow linear range. One recently described approach, is the R2 or FerriScan technique which appears to have acceptable linearity and reproducibility over the range of clinical interest (St Pierre TG, et al, 2005).....For calibration, the MRI machine must use a Phantom supplied by the company, while the data acquired is sent via internet for analysis by dedicated FerriScan software (payment per scan analysed). A particular advantage of this technique is that it can be applied with little training, at any centre with a reasonably up-to-date MRI machine”*

## References

1. Brittenham GM *et al.* Efficacy of Deferoxamine in Preventing Complications of Iron Overload in Patients with Thalassaemia Major. **American Journal of Hematology** 42:81-85 (1993)
2. Olivieri NF *et al.* Iron-chelating therapy and the treatment of thalassaemia. **Blood** 1997; 89: 739-61
3. Taher, A. *et al.* Correlation of liver iron concentration determined by R2 magnetic resonance imaging with serum ferritin in patients with thalassaemia intermedia. **Haematologica**, 2008. 93:1584-6
4. St Pierre, T *et al.* Relationship Between Serum Ferritin and Liver Iron Concentration in Hemoglobin E Thalassaemia. Abstract submitted for **European Hematology Association Congress 2011**
5. Noetzli LJ *et al.* Longitudinal analysis of heart and liver iron in thalassaemia major. **Blood** 2008; 2972-2978
6. Jensen *et al.* Evaluation of myocardial iron by magnetic resonance imaging during chelation therapy with desferrioxamine: indication of close relation between myocardial iron content and chelatable iron pool. **Blood** 2003; 101:4632-9
7. Origa R, Barella S, Argiolas GA, Bina P, Agus A, Galanello R. No evidence of cardiac iron in 20 never or minimally transfused patients with thalassaemia intermedia. **Haematologica** 2008; 93:1095-1096
8. St Pierre, T *et al.* Multicenter validation of Spin-Density Projection-Assisted R2-MRI for the Non-Invasive Measurement of Liver Iron Concentration. Paper presented at **52<sup>nd</sup> American Society of Hematology Annual Meeting 2011**. Poster downloadable from: <http://novartis.medicalcongressposters.com/Default.aspx?doc=f6a15>